

---

Subject: TB500 (Thymosin B4) + Regenerierung von Haar?

Posted by [Haar\\_Challenge\\_2021](#) on Mon, 30 Apr 2012 09:22:28 GMT

[View Forum Message](#) <> [Reply to Message](#)

---

Hatte ja schon mal einen Thread gemacht das beobachtet wurde in einer Studie das bei Wundheilung um die Wunde Haare wachsen. Mit Kupferpeptiden und Laser ist es möglich einen relativ guten effekt zu erreichen. Auch mit PRP hatten ein paar auch gute ergebnisse. Die Kopfhaut scheint mir der Schlüsselfaktor zu sein. PGD2 ist nur das Symptom von der Mikro Entzündung.

Ich vermutet diese wird durch das zu viele Kollagen verursacht ausgelöst durch MMP2 + 9

Ich bin auf Thymosin B4 gestossen das unglaubliche Wirkung auf Haarwachstum haben soll. Syntentisches Peptide ist TB500.

Thymosin  $\beta$ 4 increases hair growth by activation of hair follicle stem cells<sup>1</sup>

<http://www.fasebj.org/content/18/2/385.full>

the latest research suggests that the miniaturized follicles have the same amount of stemcells (in the bulge) as the healthy hair growing follicles.

What they found is that there are CD200 and CD34 positive hair follicle progenitor cells that are missing. These cells are normaly located at the lower bulb and in hair germ. Lower bulb and hair germ are the parts of the follicle that are responsible for creation of large anagen follicle. They are activated at the late catagen, and they recreate the anagen follicle from which the healthy thick hair grows.

Now if you understand what I just said, you would understand why we are bald. Our bald follicles do not have fully developed lower bulb and hair germ. So they are unable to grow into anagen thick follicle. (the lack of CD200 and CD34 positive progenitors).

Luckily we still have the same amount of stemcells. Stemcells in the bulge are the cells from which the missing progenitors are normaly created.

And thymuskin beta 4 is thought to be able to trigger just this. It should trigger the stemcells to become the hair germ and lower bulb. and you should reverse the miniaturisation. At least thats what the research on mice says. See the schematics i posted above. The hair germ is not pictured there, but it is normaly located just bellow the bulb. Do you see how thymosin makes the stem cells in bulge to migrate downward? thats exactly what our bald follicles are unable to do on their own. And thats exactly what makes the difference between bald follicle (the invisible vellous hair) and healthy one.

<http://www.fasebj.org/content/16/7/691.full.pdf>

TB500 wird für Doping von Pferden verwendet

Bin auch noch auf thymuskin gestossen das Patienten nach Chemo Topisch aufgetragen wird.

Die Bilder sprechen für sich.

[http://www.combat-hair-loss.co.uk/articles/thymuskin\\_reviews\\_and\\_photos.htm](http://www.combat-hair-loss.co.uk/articles/thymuskin_reviews_and_photos.htm)

Do you remember actistem (adistem) tb4-7 cream?

They used to sell it for a while but then withdrew it altogether (might be due to patents and rights that are owned by the other company now)

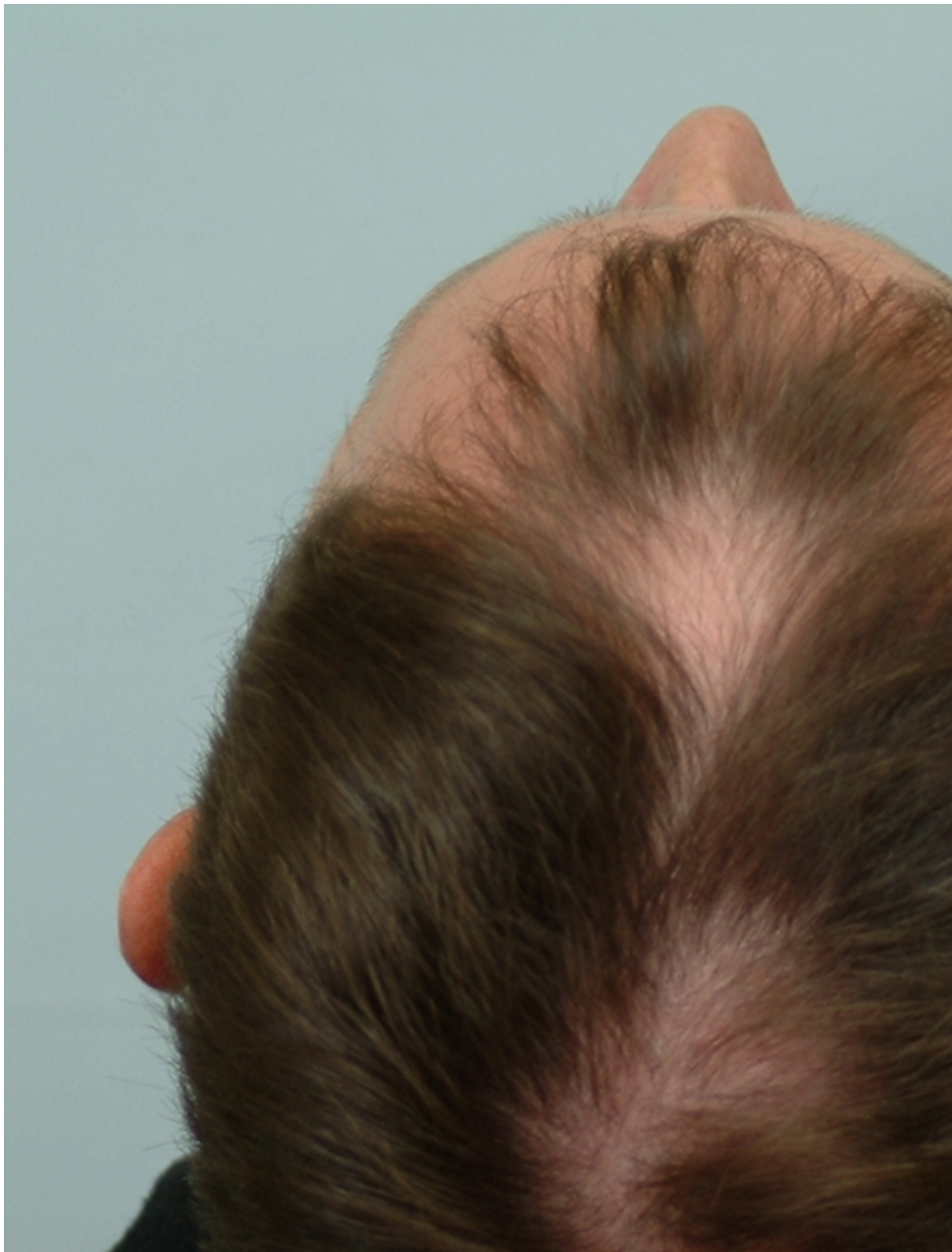As far as I was able to dig it, it seems that there was 10mg of thymosin beta 4 in 25 gram jar of the stronger version of the cream and 1mg in the normal version.

Here are some regrowth pictures adistem released at that time. they were the cream + some stemcell therapy results:

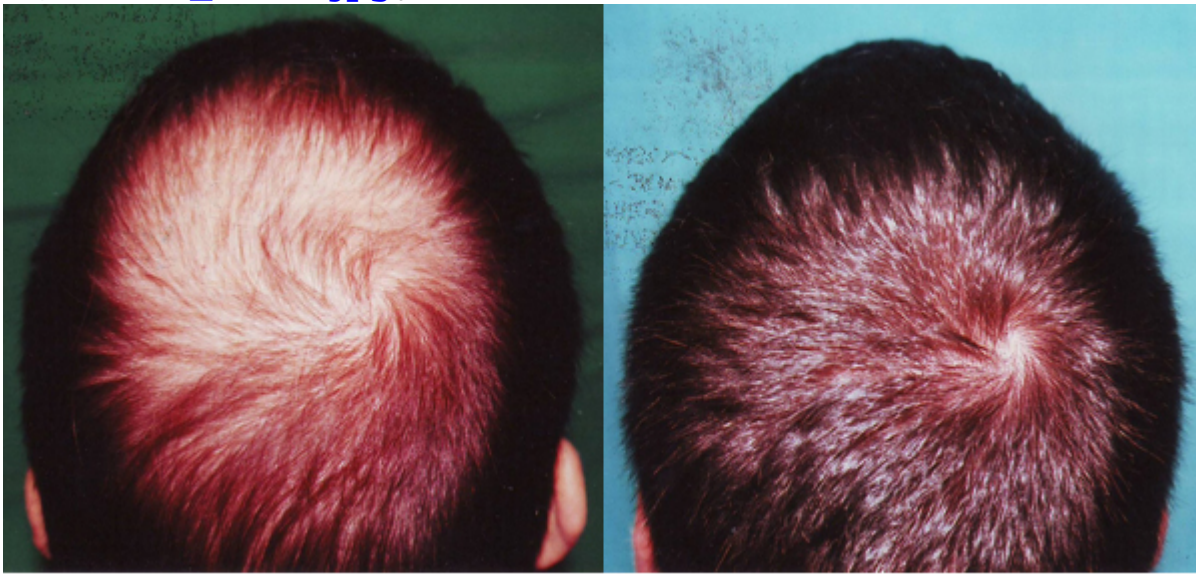
<http://www.sciencedaily.com/releases/2011/01/110104133905.htm>

### File Attachments

1) [THROMBIN.jpg](#), downloaded 579 times



2) [serum\\_ba-2.jpg](#), downloaded 548 times



**Before**

**After**