

YOUR HAIR. **OUR VISION.**  
WHERE QUALITY MATTERS



# BC HAIR TRANSPLANT - EXPERIENCE

May 2019

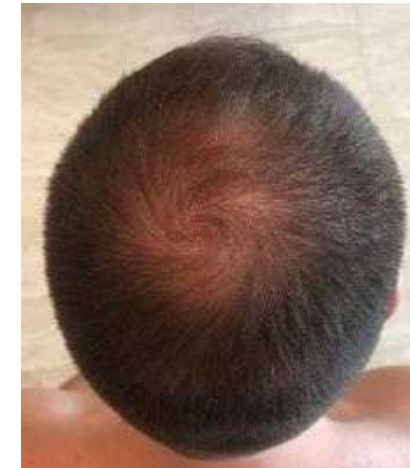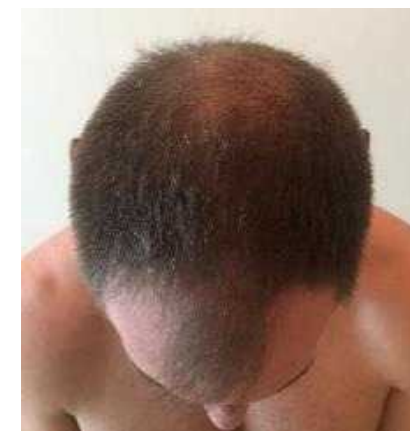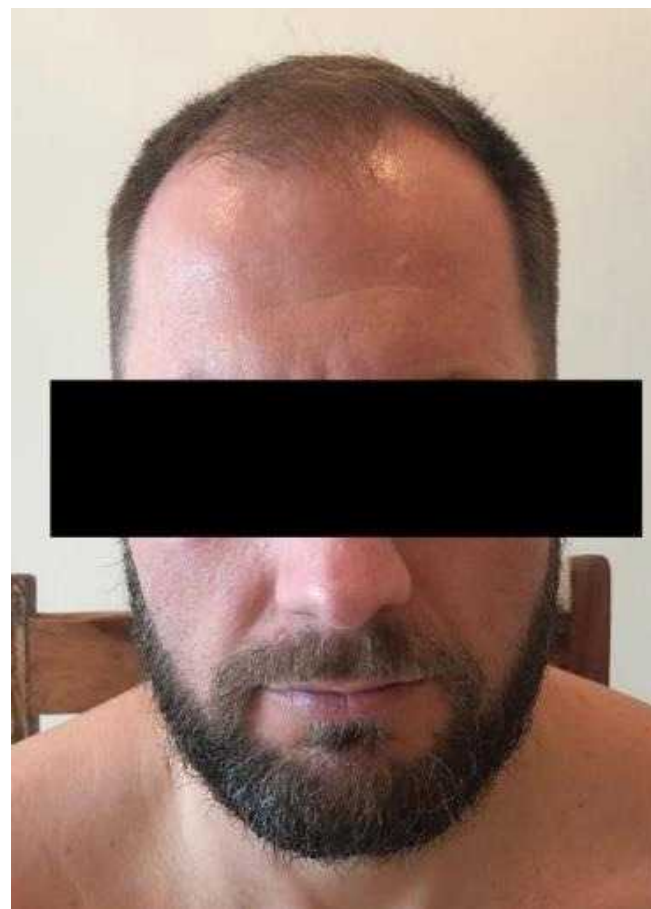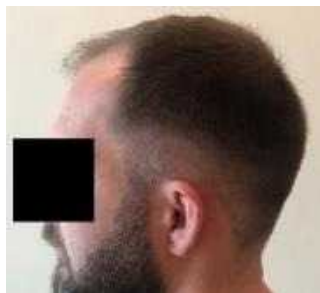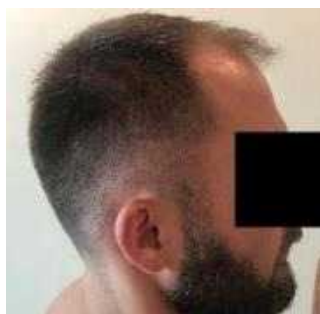# MY INTRODUCTION

- ❖ 33 Years
- ❖ Male
- ❖ NW 3-4V
- ❖ Hair-loss progressive since 20 years of age
- ❖ Father NW1-2 at the age of 30, now at 66 NW 4-5
- ❖ Method: FUE only (Rationale: Want to be able to wear short hair)
- ❖ Medication: None
- ❖ Aim: Build conservative hairline, fill in the crown
- ❖ Graft estimate after consultation: 4,000
- ❖ Graft count after surgery: 4,434

# BEFORE PICTURES – PROGRESSION & STATUS



- 1. 2009 – Age 23
- 2. 2013 – Age 28
- 3. 2017 – Age 31
- 4. 2019 – Age 32



# 3 MAIN REASONS FOR DR. COLE & FOR BCH

## DR. COLE:

- Performance:** Track record of great results.
- Experience:** 15,095 FUE surgeries.
- Pioneering & Innovation:** Dr. Cole invented the industry. The FUE tools he is using are homemade and are being sold to FUE doctors around the globe. His newest punches are highly specialized and available only to physicians he works with directly. Some other manufacturers making cheap knock off that function poorly, but are sold to inexperienced doctors, who don't know these devices destroy donor areas. Clearly he knows his tools better than any other doc.

## BCH:

- Convenience:** Travelling from the Middle East to Athens took 4h per flight. This was the fastest way to get access to a top surgeon.
- Opportunity & Pricing:** Dr. Cole is not always in Athens. A short notice opportunity at a good price came up which was making the decision easier for me.
- Competence:** DermaLab, the clinic BCH is partnering with in Athens, has a great reputation too. The people working there are very motivated, passionate, competent and patient focused.



**FORHAIR**



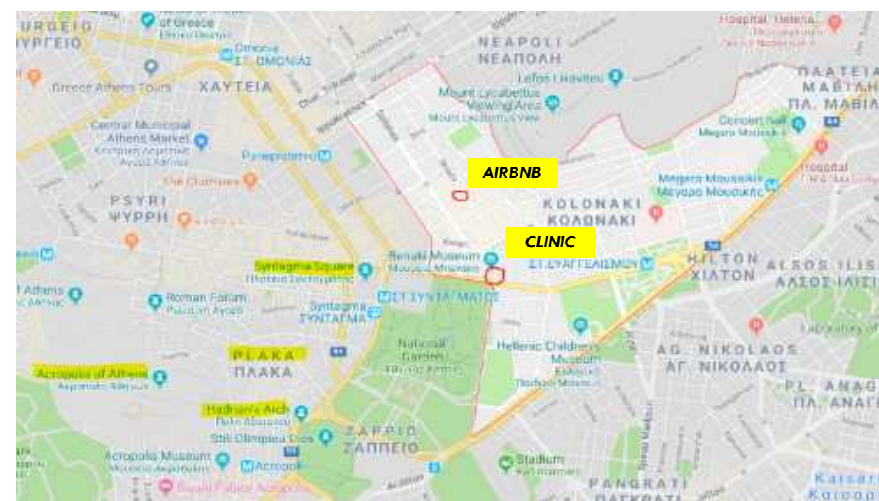
# THE CLINIC, TEAM & ORGANIZATION

**Location:** The clinic is located the premium area of the city center (Kolonaki) – whilst very central still quiet and relaxed

**Clinic:** BCH works/partners with DermaLab a reputable dermatologic clinic in Athens

## Team:

- **Ian:** Patient advisor – always reachable and helpful from day 1 until now. In two words: Genuinely cares.
- **Yannis & Krystallia + Team:** very welcoming and engaged, always ready to provide solutions to problems
- **Nicole & Lin:** very experienced team brought along by Dr. Cole, responsible for the implantation of grafts



Krystallia  
Kyparissou, MD



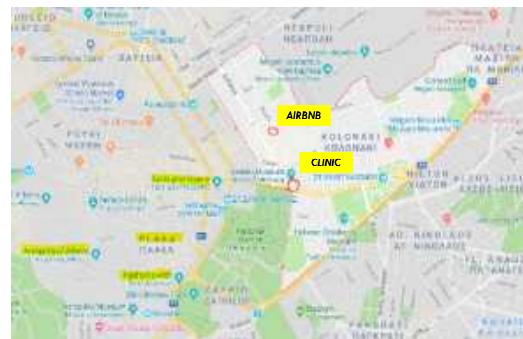Yannis  
Venetsanos, MD

# 24<sup>TH</sup> MAY 2019 – ARRIVAL ATHENS

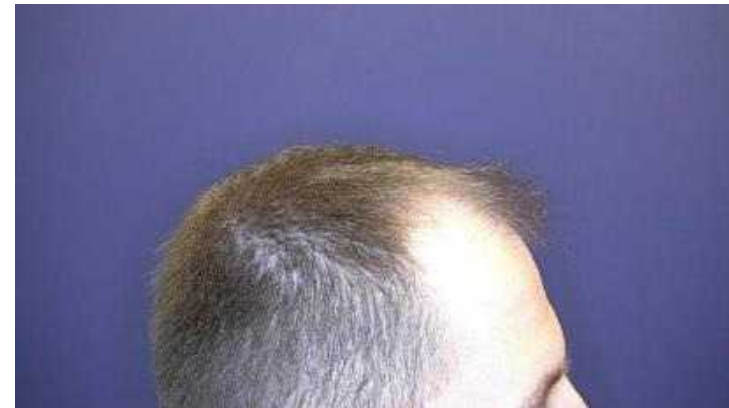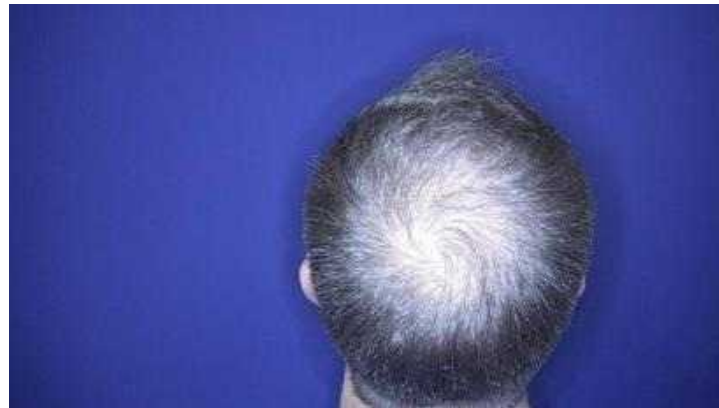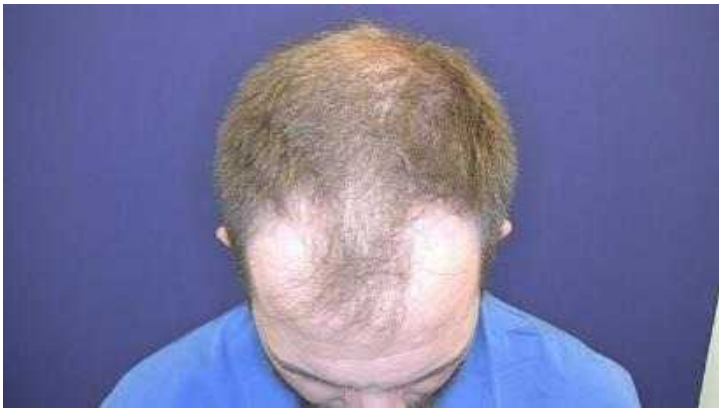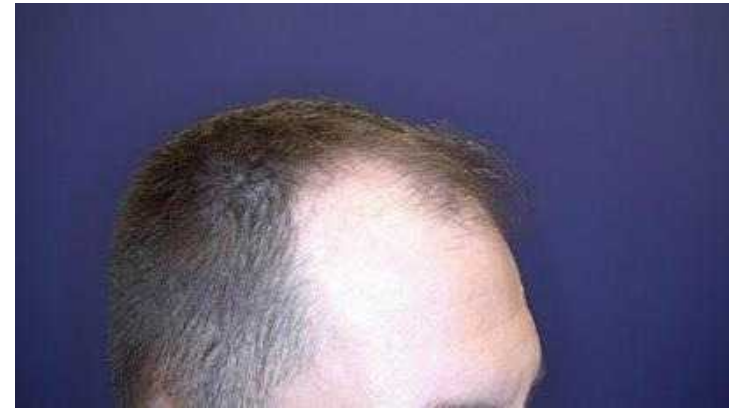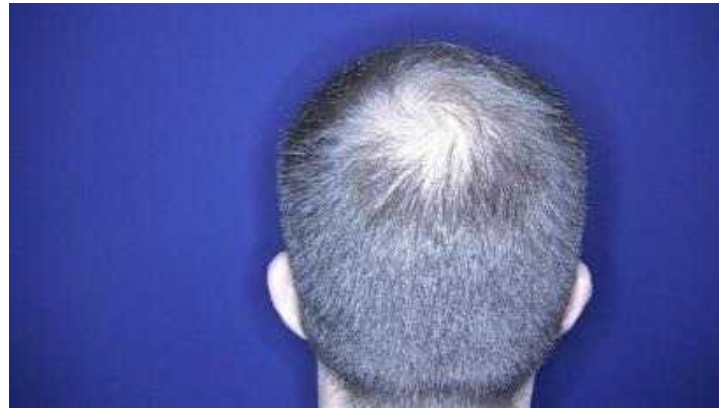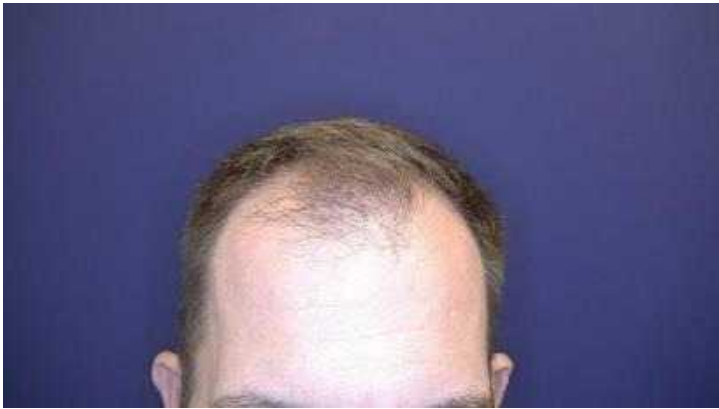**Our Airbnb:** As this was a last minute booking we did not have much of a choice. Whilst wanting the convenience of a hotel we could not find available rooms at reasonable prices close to the clinic. Hence, we have decided to book an Airbnb, which turned out to be the perfect decision.

**Neighborhood:** Kolonaki is probably one of if not the best place to stay in Athens. It's a 10 minute walk into the city center (which was brilliant for my partner who accompanied me on the trip) and a 5 minute walk to the clinic. Overall it is a premium neighborhood incl. prominent luxury brand representations, A Carrefour Supermarket close by (comes in handy for breakfast options and late night snacks in case you are returning tired from the surgery and or one does not want to present his/her big bloody head to the public.

**Athens Tour:** The day of our arrival was for our leisure in its entirety. We decided to have a walking tour through Athens. This needs to be booked in advance... and is totally worth it. The guides are (usually) students that will ask you for a small tip if you enjoyed the tour. We most definitely enjoyed the tour and our first impressions of Athens



# IMMEDIATELY BEFORE SURGERY — CLINIC PICTURES

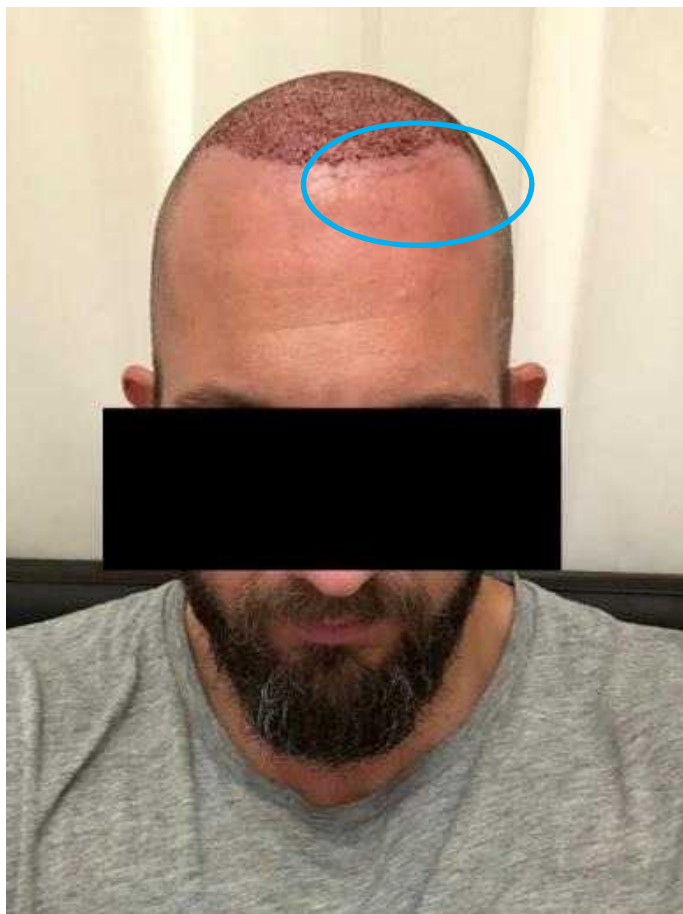
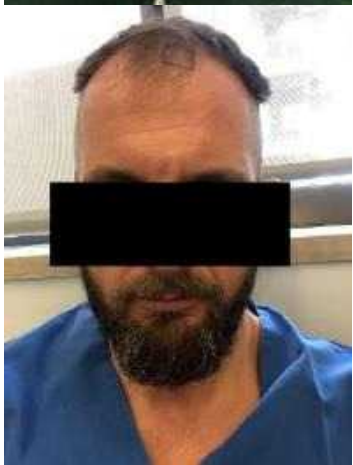
# 25<sup>TH</sup> MAY 2019 – SURGERY DAY 1

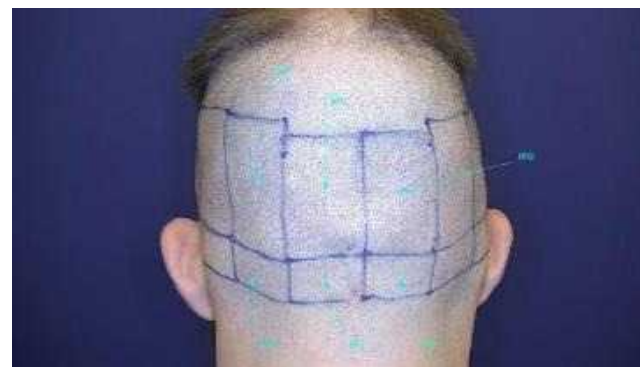
- 8-10AM Arrival at clinic, Payment, Patient agreement signatures, Health Check - self assessed, Donor area shave, Before Photos, Hair Count (Donor, Recipient).
- 10-12AM Dr. Cole arrival: Consultation & Hairline design; followed by complete shave.
- 12-10PM Surgery: First the anesthetic injections, which clearly were the most painful part of the surgery; yet absolutely bearable. I would consider myself relatively pain resistant and over all have not experienced “anything close to” unbearable pain. It can happen that the anesthetics are fading away during the procedure (happened to me as well). In that case the patient will only need to raise this and will be relieved immediately and within seconds. Dr. Cole started the graft extraction very carefully. During the first part of the surgery he has adjusted his extraction equipment to personalize to my hair type in the donor area. He has purposely only extracted 1 side of the donor and implanted only on the same side of the crown. I experienced the procedure as very organized, clean and competent. Dr. Cole is the only person in the room who extracts grafts and creates the incisions. The team around him is supporting at all times. Two very experienced nurses/technicians are implanting the grafts under his observation. Dr. Cole clearly seems to have every eventuality under control. His calmness served as is an indicator of experience and professionalism. Dr. Cole takes breaks after extraction and leaves his experienced nurses to implant grafts. At the end of the surgery he checked the result thoroughly.
- 10-12AM Bed Time: After dinner I took antibiotics provided by the clinic & slept on the donor side that has not been harvested during surgery day 1. Ibuprofen is provided by the clinic. I have taken one of the two pills provided. Did not have much pain but wanted to ensure that I am not waking up in pain during the night. This worked well for me.



# 25<sup>TH</sup> MAY 2019 – SURGERY DAY 1

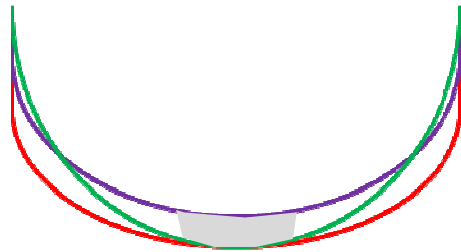


1. Image from the morning before the surgery.
2. Image with shaved donor area before surgery – recipient not shaved for Dr. Cole to support hairline design.
3. Image after the first day of surgery – work has been done from the front to the back. The hairline achieved on day 1 is the very conservative hairline drawn in the morning. The more aggressive hairline is still visible underneath the implanted area. Note: there is a swollen area on the right side of the head.
4. Donor before: on day 1 slightly over 2,200 grafts have been harvested/placed.



# 26<sup>TH</sup> MAY 2019 – SURGERY DAY 2

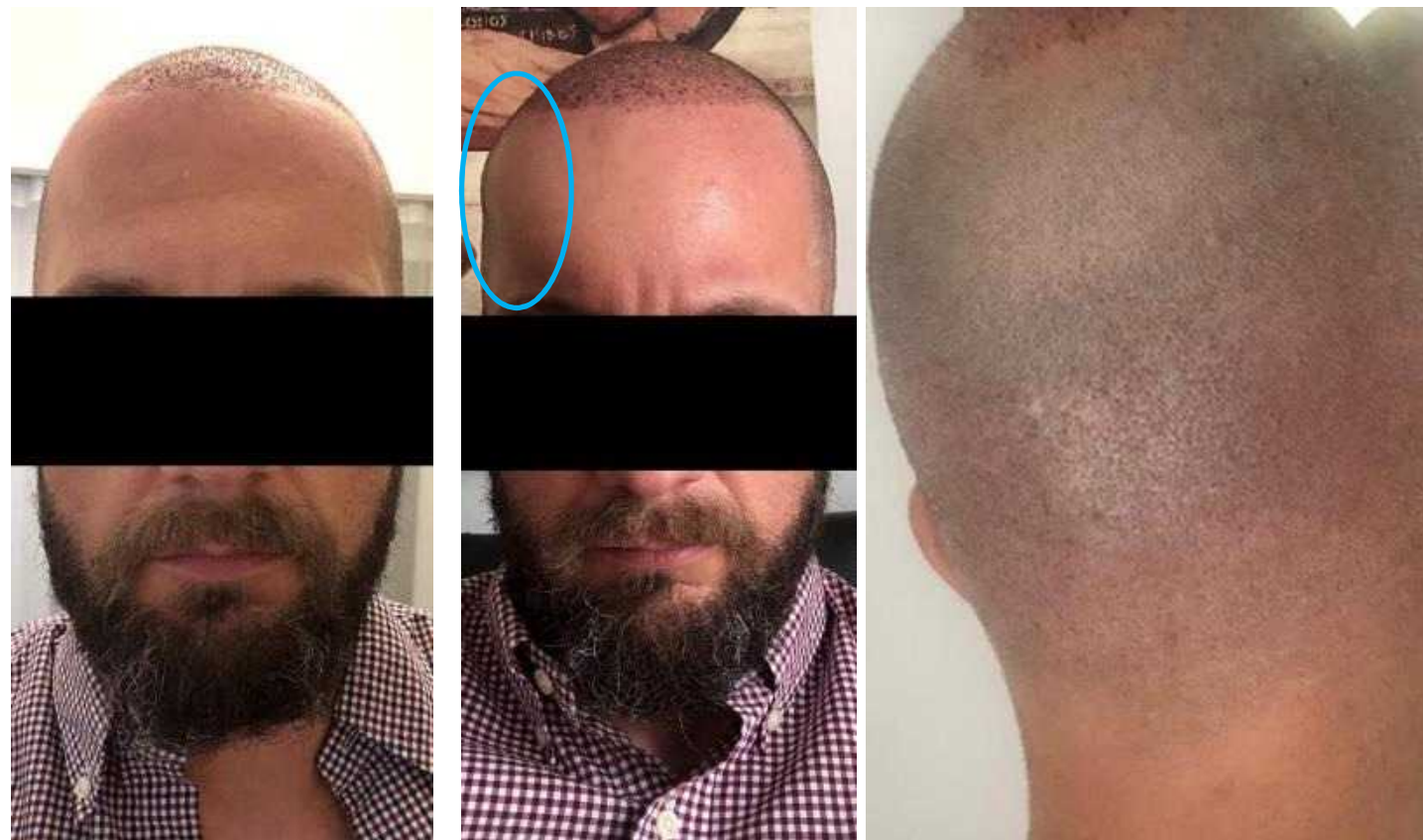- 10AM Check up followed by anesthetic injections
- 11-9PM As per the previous day Dr. Cole did the harvest, this time on the other side of the donor, and the incisions. Step by step and little by little Dr. Cole went closer to the desired hairline. Dr. Cole has eventually concluded that a hairline design between conservative and aggressive would be best to follow. Due to many reasons one being that native hair is still growing in that area. The final hairline design is as per the below illustration. Also the crown has been filled on the other side during the day. Lunch has been provided (as per the previous day) and there will be time dedicated to take a break to eat. Generally I was free to take breaks at any point in time during the procedure. I have asked the doctor/nurses/technicians for the best times to break to ensure smooth, efficient and uninterrupted operations.
- 10-12AM Bed Time: As per the previous day. This night I was instructed to sleep on the donor side that has been harvested the previous day. Again I have taken the Ibuprofen provided by the clinic to avoid a sleepless night.



- Red: Aggressive Hairline
- Purple: Conservative Hairline
- Green: Final Hairline
- Grey: Area of (thin) native hair

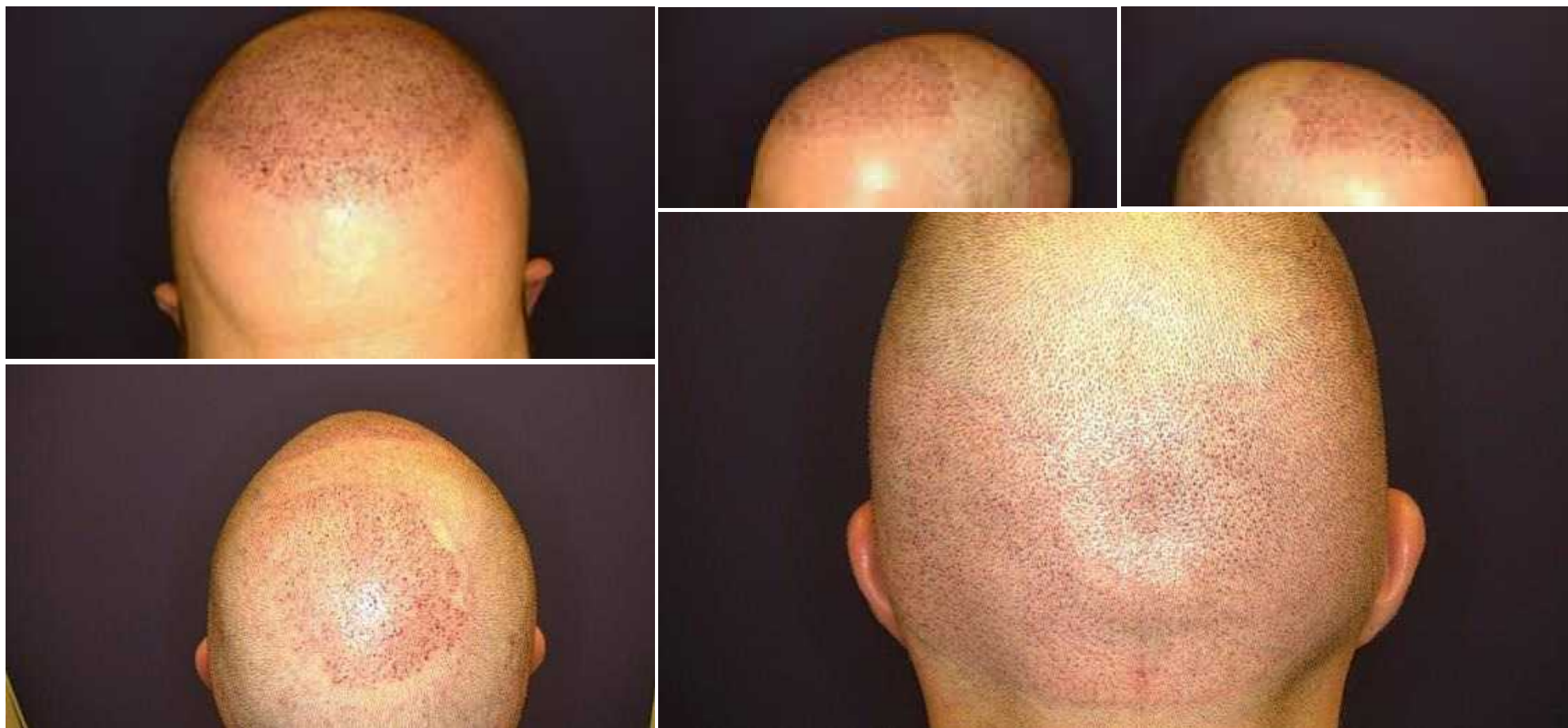*\* for illustration only*

# 26<sup>TH</sup> MAY 2019 – SURGERY DAY 2

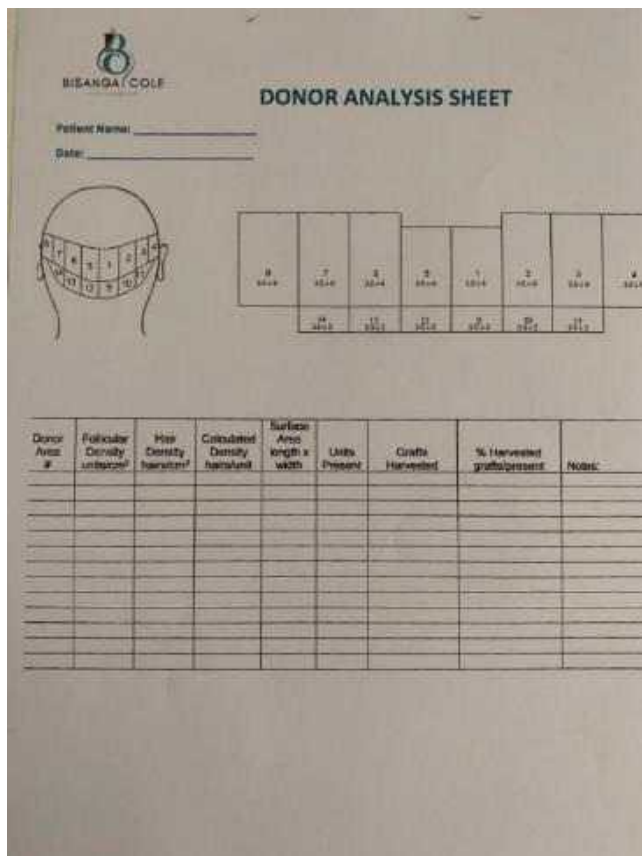


1. Image from the evening after the 2<sup>nd</sup> surgery day
2. Image from the morning after the 2<sup>nd</sup> surgery day – it is clearly visible that the hairline did come down to the desired level. Note: there is a small swollen bump on the left side of the head.
3. Image from the morning after the 2<sup>nd</sup> surgery day – the donor area was much better than I expected. I have clearly seen and read about much worse in various forums and was obviously very happy with the condition of my donor – also no pain killers needed (this is a general comment – I have not taken any painkillers; except for the ones before sleeping as previously mentioned)

# IMMEDIATELY AFTER SURGERY — CLINIC PICTURES



# THE MORNING AFTER SURGERY — THE NUMBERS



Extraction Box	Number of Grafts Extracted
Box1	472
Box2	606
Box3	460
Box4	402
Box5	412
Box6	361
Box7	271
Box8	320
Box9	144
Box10	115
Box11	58
Box12	150
Box13	108
Box14	124
<b>Total</b>	<b>4003</b>

Type	Number of Grafts Implanted
Single	380
Double	1865
Triple	1541
Quadruple	568
5-6	81
<b>Total</b>	<b>4434</b>

Extracted:	4003
Implanted:	4434
<b>Total</b>	<b>431</b>

Implanted Crown: c. 1,600 grafts

Implanted Front: c. 2,800 grafts

Punch Sizes: 1.1 // 1.0 // 0.9 // 1.15

Depth: 3.5

Notes from the clinic on the discrepancy between extracted and implanted:

- In order to achieve the final number of singles (apparently very rare on my head) to ensure the design of the hairline doubles had to be split to create sufficient number of singles.
- That does not explain the remaining difference of c. 50 grafts that have either not been counted when extracted or double counted when implanted.

# PRODUCTS USED



The following products were provided/prescribed by the clinic for after-care:

- Antibiotics
  - For 4 days after the surgery 2x daily
- Eau Thermale Spray
  - Applied 2x daily on scalp until empty
  - I have actually purchased 2 bottles and used those till day 20 (not mandated by the clinic)
- A-DERMA Foaming Gel Shampoo
  - Used 1x day for the first 7 days after surgery – foam left 3m left on scalp
  - Used 2x day for day 8 until empty (day 20 for me) – foam left 3-5m on scalp
  - From day 8 light circular massage with fingertips
  - Hint: making foam in hands as described by the clinic can be a bit tricky I found it easier to put some gel into a plastic bottle and shake it until thick foam can be applied from the bottle directly onto the hair
- A-DERMA Repairing cream
  - Applied 2x daily on donor (morning and night before bedtime)
  - From day 14 also on scalp (very gentle)

# THE HAT/CAP

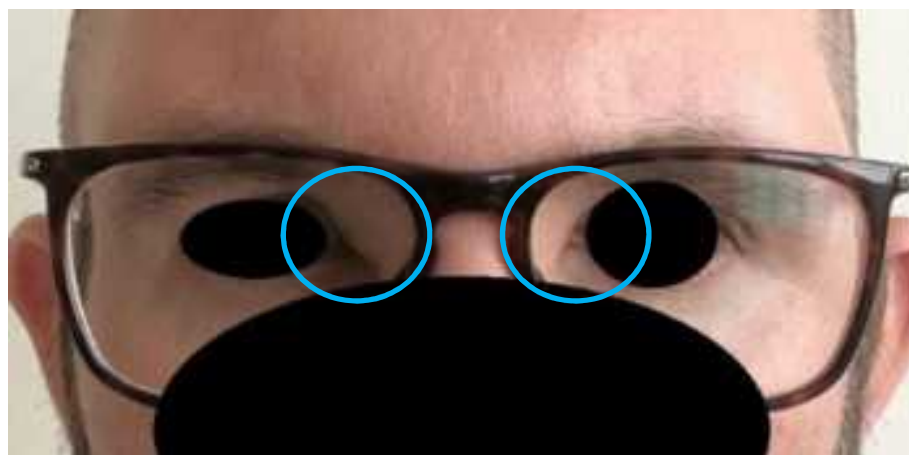
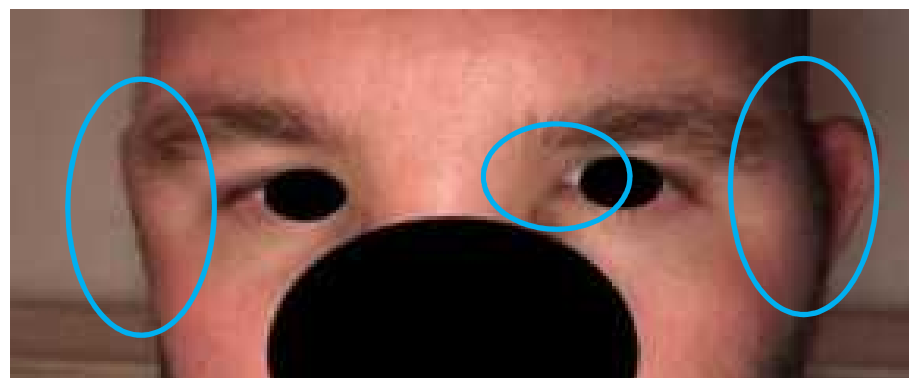
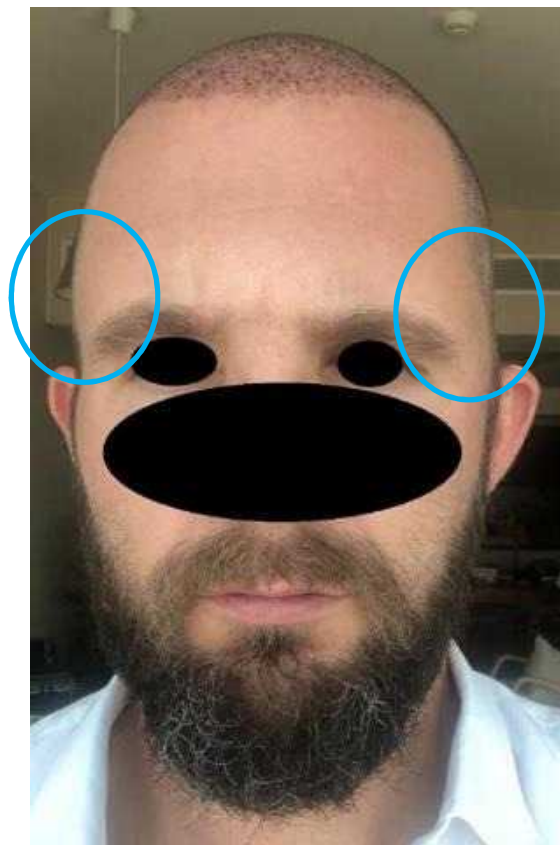

I have been shopping around quite a bit before surgery and bought a collection of caps and hats to make sure one will comfortably fit for the travel after the surgery.

I found the UA Flat Fit cap the best option as it has plenty of space/air pockets in the front when fitted. It also has the adjuster that helps to get the right “pressure” in place to make sure the cap does not sit on the implanted grafts in the crown area.

Hint: Airplane – ask for a window seat & seat your partner/companion in the middle – tip: ask for a seat in the back of the airplane – you can see what’s going on in the front and behind you is a wall only – so nothing unexpected coming from above/back. Helped me psychologically to get through the flight, also because you know that nobody is staring on your crown – makes it easier to feel comfortable taking off the cap.

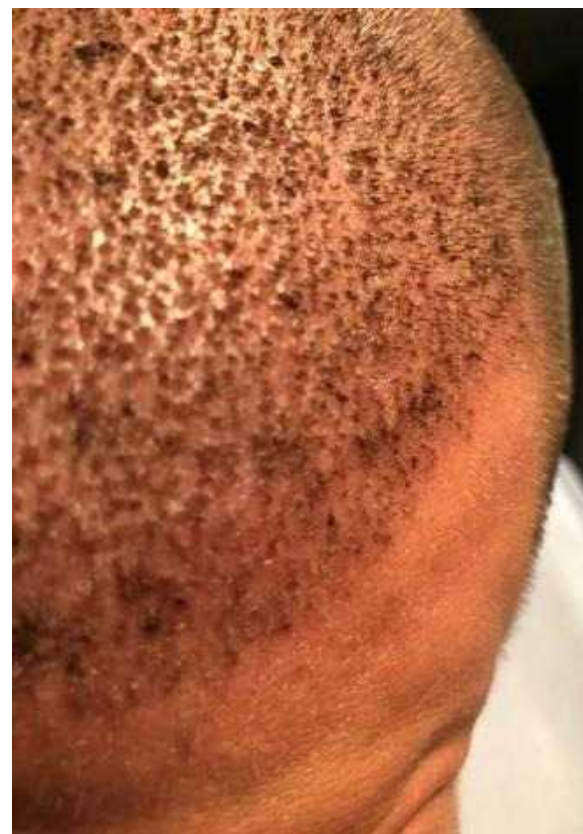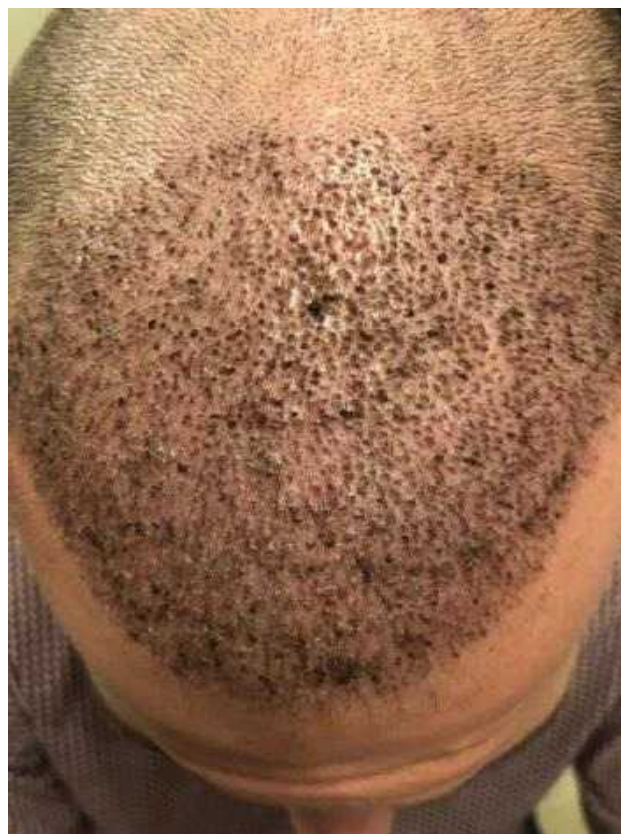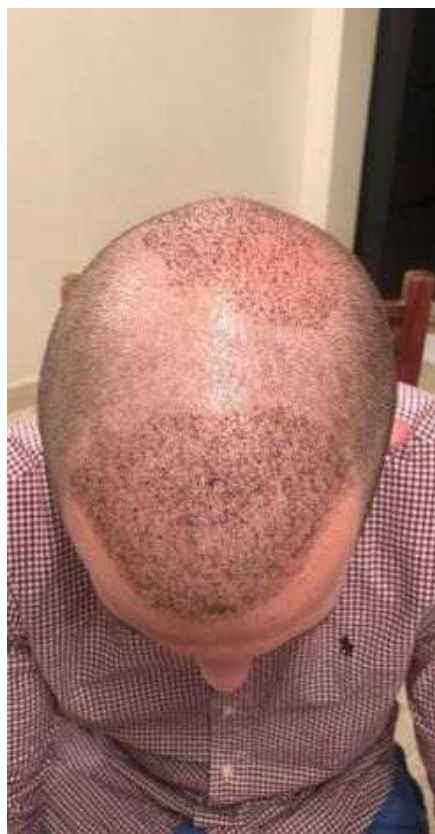## 28/29<sup>TH</sup> MAY 2019 – HOME (D2+D3)



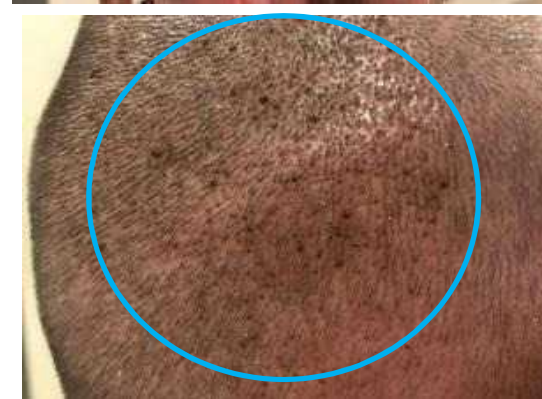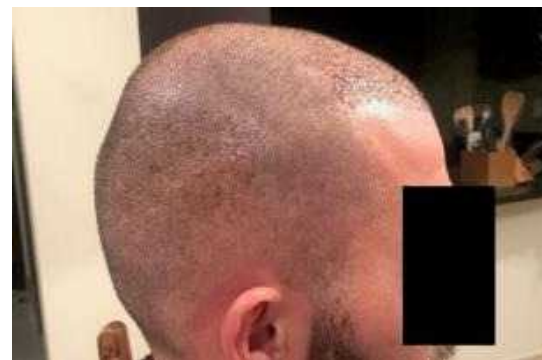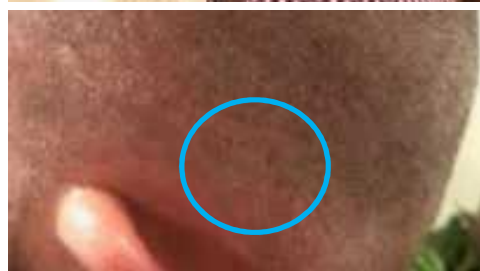
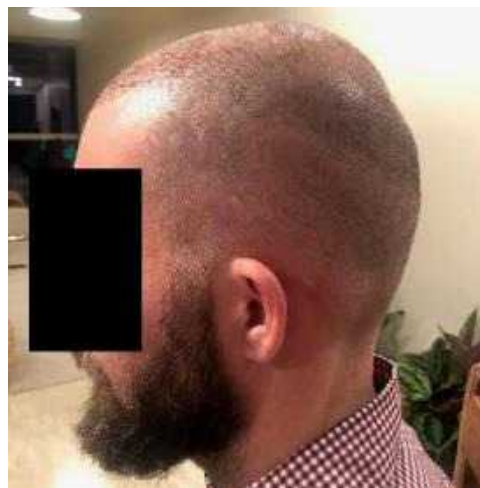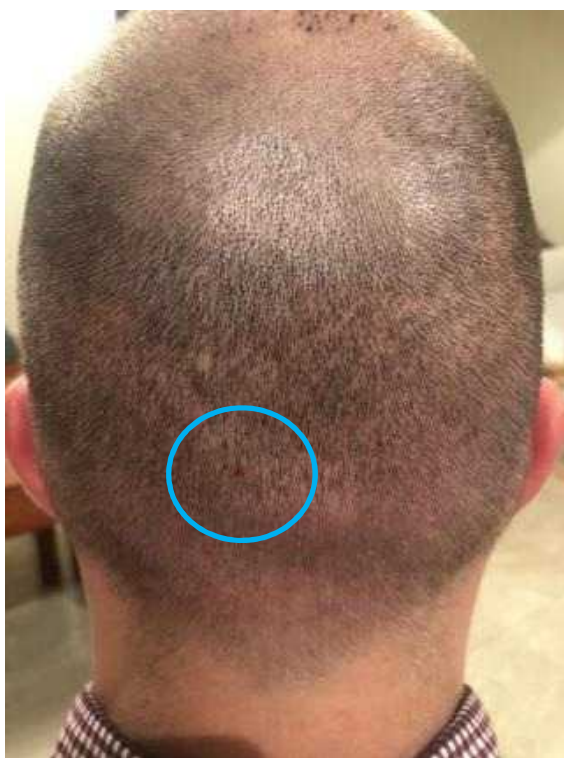Swelling: I have been sleeping as instructed for the first days. 45 degrees inclined upper body to help with the swelling. The images show the worst status of swelling throughout my recovery. They are taken on day 2 and 3 post surgery. I have tried my best to point out the affected areas. Clearly I had a hard time to point out the swollen areas. This is as bad as it got for me. From a growth progress perspective there is not much to add other than that the hair in donor and recipient area are continuing their growth slowly but surely.



30<sup>TH</sup> MAY 2019 — HOME (D4)



# 30<sup>TH</sup> MAY 2019 — PHOTO SESSION (D4)



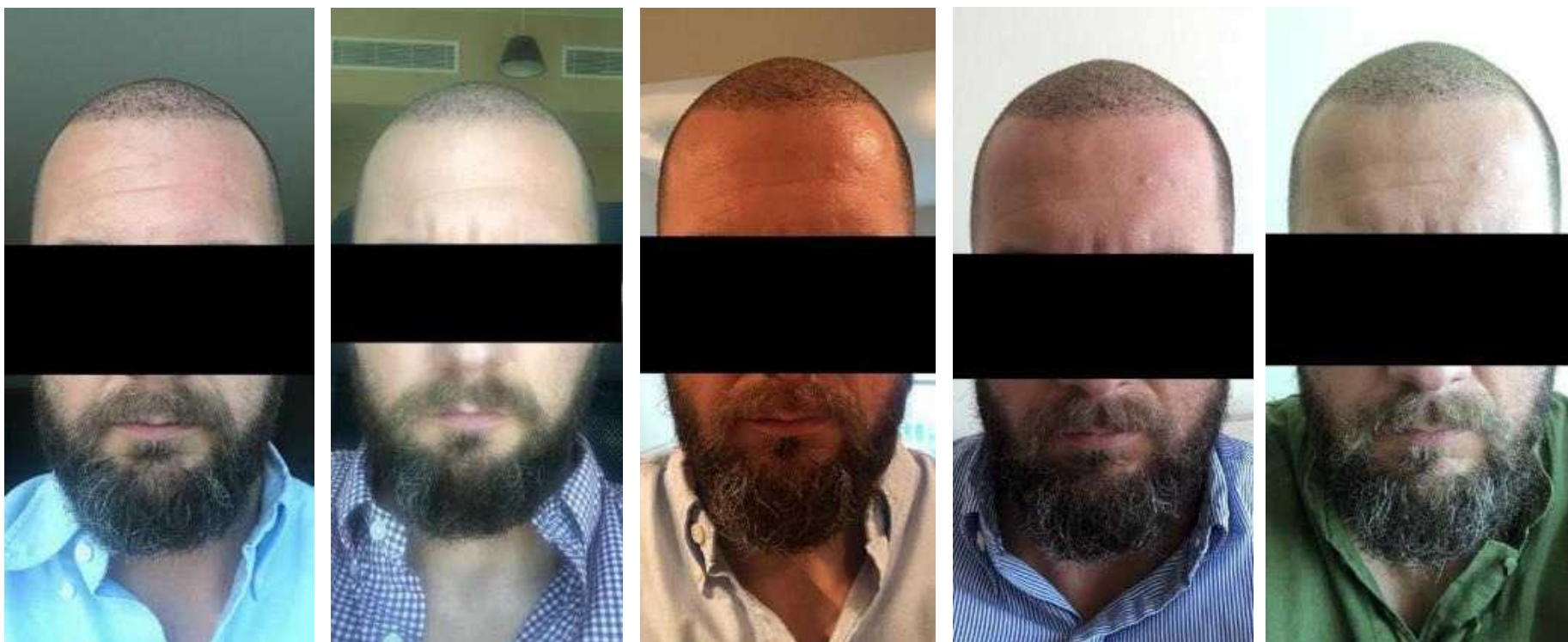The donor area is mainly healed with smaller crusts remaining on the sides.

The donor area harvested on the first day is shown on the right side.

The donor area harvested on the second day is shown in the middle.

The second day donor is in a better shape compared to the first day. This is due to the fact that a smaller punch was used to extract singles and doubles.

# 29<sup>TH</sup> – 2<sup>ND</sup> JUNE 2019 – HOME (D3-7)



## HAIR-FALL — D5-7 & D8



Between day 5 and 7 I noticed early shed hair on the bedsheet. This is nothing to be concerned about and the rule of the thumb is that as long as there is no bleeding the loss of a graft is very unlikely.

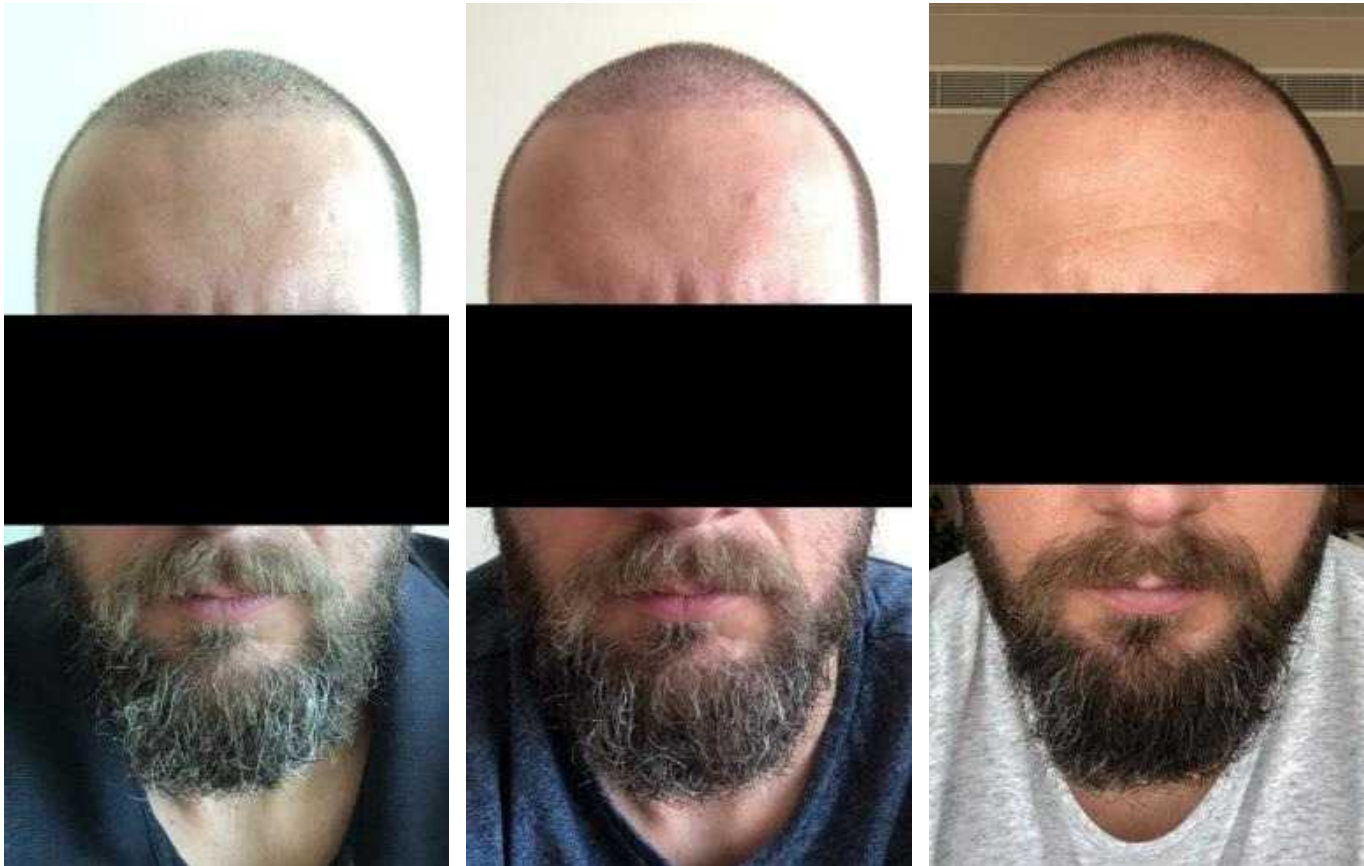Day 8 is the first day of washing + circular finger massage. I found my sink full of shed hair and softened scabs. It felt good to touch the scalp again. Numbness though is still present.

On Day 9 the shedding continues with lesser scabs left on the scalp to be removed by the massage.

Day 10 is the day were all scabs have fallen. Numbness still being present.

Afterwards hair will continue to fall until approximately week 5.

## 3<sup>RD</sup> – 6<sup>TH</sup> JUNE 2019 – HOME (D8-10)

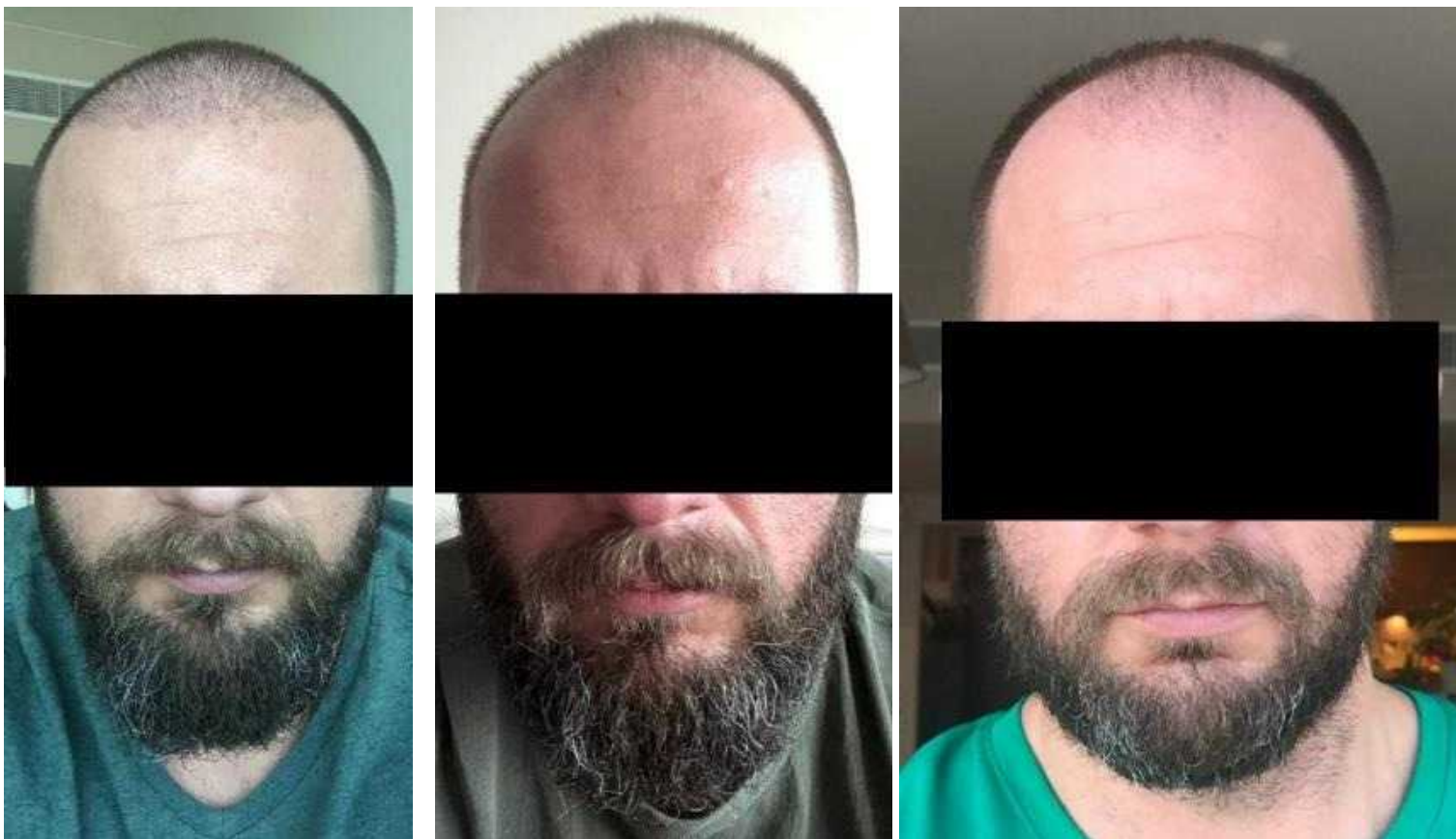

Day 8 is the first day that involves shampooing + circular massage on the recipient area. Scabs are still visible on the top of the scalp. The crown area was clear of scabs after day 8.

Day 9 shows very few scabs left on the scalp. Also day 9 is according to Bernstein's published research paper the day were grafts are fully and permanently anchored.

Day 10 is the day were BCH is expecting the patient to be scab – free. I can confirm this being the case for me.

# 10<sup>TH</sup> – 29<sup>TH</sup> JULY 2019 – HOME (D14/21/M1)

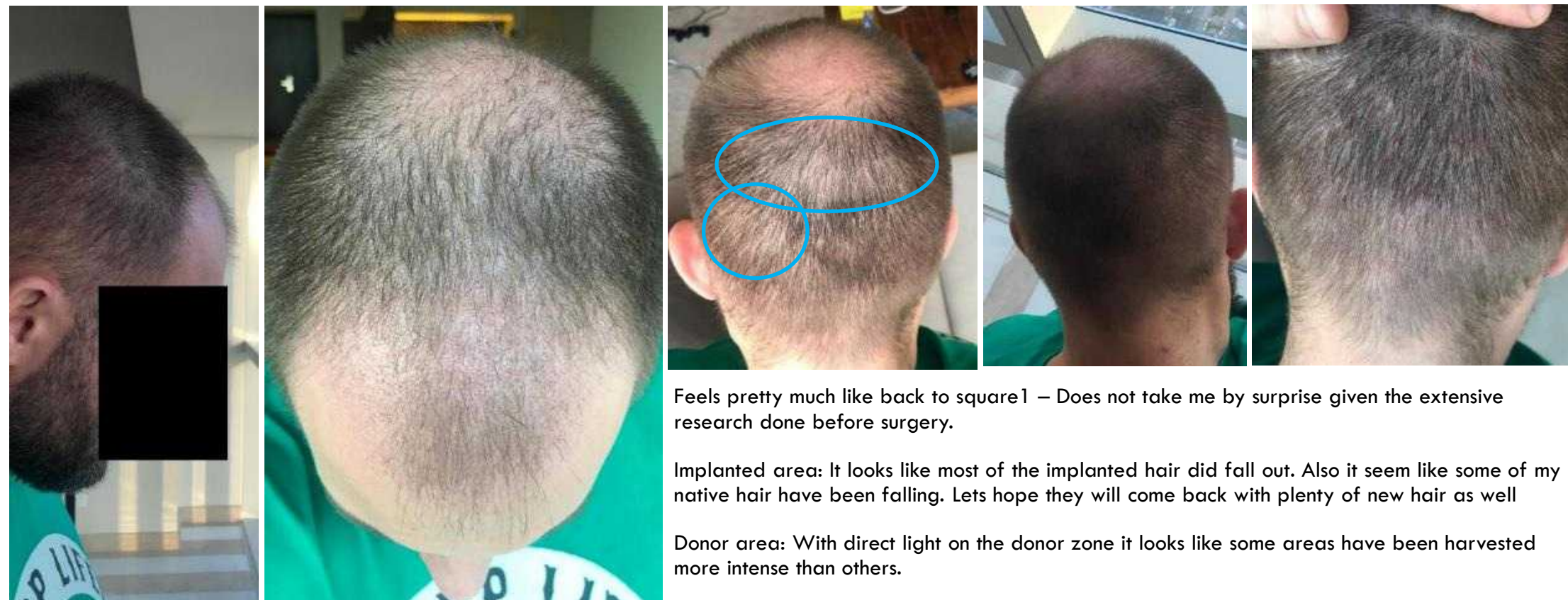

Day 14 still shows implanted hair in its position. Despite a good level of shedding the hairline design is still easy to see.

Day 21 now shows that a significant amount of implanted hair has fallen out. I have buzzed down the sides to 3mm.

A few days after M1 I have taken the last picture (more in the next slide). My view and observation is that I have lost all my implanted hair and some of my native hair.

# 29<sup>TH</sup> JULY 2019 – HOME (D14/21/M1)



Feels pretty much like back to square 1 – Does not take me by surprise given the extensive research done before surgery.

Implanted area: It looks like most of the implanted hair did fall out. Also it seem like some of my native hair have been falling. Lets hope they will come back with plenty of new hair as well

Donor area: With direct light on the donor zone it looks like some areas have been harvested more intense than others.